



The Effect of Advanced Laser and Interferential Therapy on the Patient of Pes Anserine Bursitis in Occupational Rehabilitation- A Case Report

Ekta Kharde¹, Satyam Bodhaji², Khan Madiha³

¹MPT Sports, MGM school of physiotherapy

²Associate Professor, Royal college of physiotherapy

³MPT Musculoskeletal, MGM School of physiotherapy

ABSTRACT: A 30-Year-old male came to hospital with primary complaint of medial side right knee pain. Patient is watchmen by profession and involve long time standing without rest. He was diagnosed for pes anserine bursitis which is inflammatory condition. The aim of the present study is to implement advanced physiotherapeutic intervention with the conventional method for the better and long-term therapeutic effect in point of occupational rehabilitation. The study result concluded that interferential therapy with advanced laser therapy gave significantly swift and long-term effect followed by strength and conditioning of the lower limb. Procedure- a treatment session of 2 weeks included application of IFT and laser at lesion site to facilitate the response of pain and tenderness. We have used the pain scale, which is a visual analogue scale, to assess the efficacy of the modality. For 15 minutes, the patient received laser and IFT treatment. Conclusion- combining IFT and laser therapy can be used to treat pes anserine bursitis.

KEY WORDS: laser, pes anserine bursitis, ultrasound.

INTRODUCTION

Soft tissue musculoskeletal pain syndromes may occur alone or as a result of underlying mechanical derangements or systemic inflammatory disease, accounting for up to 30% of all primary care office visits. Bursitis is an inflammatory condition that affects the bursae, which defend soft tissues from bony prominences and friction caused by structural motion. (1) Bursitis is the umbrella word for Inflammation of the bursae, bursae are cavitory structures lined with synovial tissue that cushion and aid joint and muscle motion. bursa is a fluid field sac with cavitation structures lined with synovial tissue. Tenderness, pain, redness, and swelling are some of the most common signs and symptoms seen in pes anserine bursitis. The medial knee and upper tibial area are the most common locations for this pain. The semitendinosus, gracilis, and Sartorius muscles tendon are inserted at the medial knee. (2) There have been several studies on the condition of pes anserine bursitis; in this research, we used advanced laser therapy & IFT followed by strength & conditioning of the lower limb & in this case report present the effect of laser & interferential therapy to correct the right side of knee pes anserine bursitis in a 30-year male.

CASE PRESENTATION

A 30-year-old man presented to the hospital with a primary complaint of pain in the right side of his leg. He works as a watchman and has a history of traffic accidents. Patient went to the nearest hospital for an examination, but no fracture, ligament, or meniscus damage was discovered; but, after taking medicine, his pain subsided. He resumed his everyday life after the trauma, but after two months, he complained of severe pain and noticed swelling on the right side of his knee below the patellar bone. He went to an orthopedician, who advised him to use a cane because he couldn't bear weight due to the pain, and referred him to physiotherapy because MRI revealed he had pes anserine bursitis. When he first came in for physiotherapy, he scored his pain on a visual analogous scale of 8 during exercise and 3 during rest (fig.1). His pain was persistent in nature, and he complained of sharp shooting pain that was exacerbated by walking and long periods of standing. The patient also said that he felt relief after resting and taking medicines.

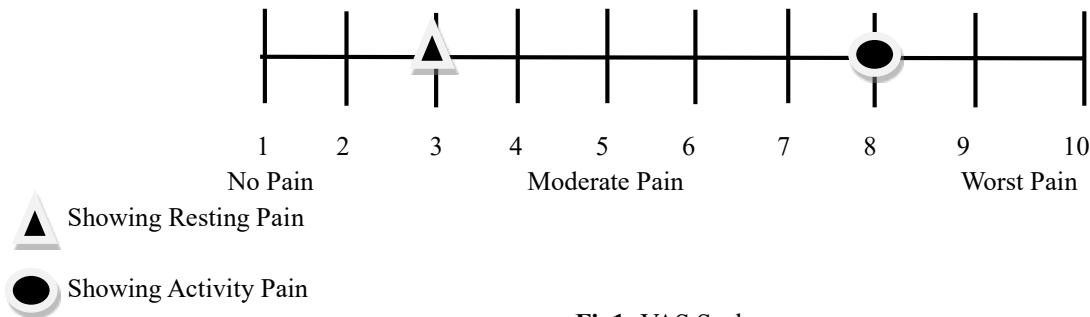


Fig1: VAS Scale

Clinical examination

He had lordotic posture at first, and he also complained that his weight had risen over the previous month. He struggled to walk and had an altered gait style, as well as using a cane. Swelling on the right side of the knee was found & grade 3 tenderness on the inner side of the knee below the patella. The active phase was painful and restricted, and the right knee's strength was also diminished, which showed in table 1

Table 1

AROM	RIGHT	LEFT	MMT	RIGHT	LEFT
Knee			Knee		
Flexion	40	130	Flexion	3	5
Extension	10	0	Extension	4	5

Diagnosis

He is diagnosed with pes anserine bursitis on the basis of subject & objective examination.

Prognosis- patient was co-operative & he willingly participated in all rehabilitation programs & those progressions were good.

Therapeutic intervention- Low level laser therapy -10-20 min wavelength in the ranges of 760-850 nm, density 5m W/cm² at 5 cm deep when beam power is 1 watt & surface density 5 W/cm²

4 Clinical target-

1. To promote healing & reduce inflammation - site of injury.
2. To reduce edema & inflammation-lymph node
3. To induced analgesia-nerve
4. To reduced tenderness- trigger point

IFT- clover leaf model, 10-15 min

To reduced pain -week 1

THERAPY	MODE	DURATION
LOW LEVEL LASER THERAPY	5mW/cm ² at 5 cm deep Power 1 watt and surface density 5 W/cm ²	10-20 Minute
IFT	Clover leaf model	10-15 Minute
CRYOTHERAPY		10 Minute

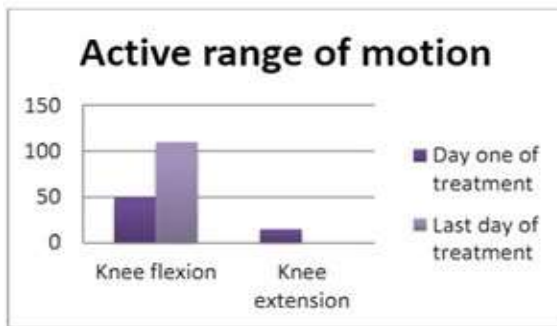
To improve strength- week 2

THERAPY	MODE	DURATION
AROM (knee flexion, extension)	TheraBand	10 Repetition, 3 set
Squatting	Flat surface, BOSU ball training	5 Repetition, 2 set

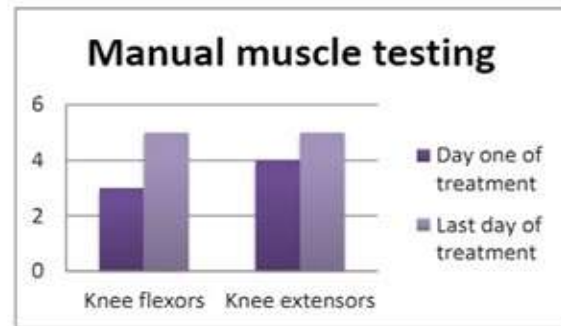


Follow ups & outcomes

Patient was cooperative: in comparison to the first visit, the patient felt at ease; in the most recent visit, the severity of pain was decreased to a 2/10 VAS during exercise and a 0/10 VAS during rest and other times. His life was made better. Patient was cooperative; in comparison to day one, he felt during ease. At his most recent visit, the severity of pain was reduced to a 2/10 VAS after exercise and a 0/10 at rest and other times, and his quality of life was enhanced. He would now walk without the use of a cane, and his strength had significantly increased. The discrepancy between his first and last day of manual muscle testing is seen in the graph (A) & AROM in graph (B)



(A)



(B)

DISCUSSION

Pain on the inside of the knee and lower leg are typical symptoms of pes anserine bursitis, Physiotherapy plays a critical role in this situation. Downing DS et al (1986) confirmed the therapeutic benefit of ultrasound in the treatment of subacromial bursitis; patients with supraspinatus tendinitis, subacromial bursitis, and adhesive capsulitis were treated with ultrasound early. This research was designed to see whether we could use ultrasound in addition to a generalised procedure to reduce pain and increase range of motion. However, this study concluded that ultrasound had no beneficial effect in pes anserine bursitis, so we did not use ultrasound in our study.

The Cotler HB et al (2015) they said there were few side effects and it was well accepted by the elderly when they identified the therapeutic use of low-level therapy in musculoskeletal pain. LLLT is Said to be useful for pain management and can speed up the body's ability to heal itself. However, LLLT can Only be used as an adjunct treatment for pain relief in patients. We have successfully combined LLLT with IFT. Fuentes JP et al(2010) stated that adding another intervention to a control procedure at discharge and a placebo three months later seemed to be more effective at reducing pain than a control procedure alone. IFT used in a multimodal treatment plan tends to relieve discomfort in acute and chronic musculoskeletal pain as compared to no drug or placebo.

Ezzati K et al (2020) Look at the advantages©/high-intensity laser therapy and co-intervention in the treatment of musculoskeletal pain. Furthermore, several studies have shown that ultrasound and laser therapy are highly effective in reducing pain and improving range of motion. when applied to patients with pes anserine bursitis. The current research looked at the effects of ultrasound and laser on pes anserine bursitis. In this case study, the application of IFT and laser resulted in an effective rate of 80 percent.

CONCLUSION

Standing employees are more likely to develop pes anserine bursitis, and the IFT and laser will also help to relieve pain and improve quality of life.

REFERENCES

1. Hubbard MJ, Hildebrand BA, Battafarano MM, Battafarano DF. Common Soft Tissue Musculoskeletal Pain Disorders. Prim Care. 2018;45(2):289-303. doi:10.1016/j.pop.2018.02.006
2. Mohseni M, Graham C. Pes Anserine Bursitis. In: StatPearls. Treasure Island (FL): StatPearls Publishing; November 26, 2020.



3. Downing DS, Weinstein A. Ultrasound therapy of subacromial bursitis. A double blind trial. *Phys Ther.* 1986;66(2):194-199. doi:10.1093/ptj/66.2.19
4. Cotler HB, Chow RT, Hamblin MR, Carroll J. The Use of Low Level Laser Therapy (LLLT) For Musculoskeletal Pain. *MOJ Orthop Rheumatol.* 2015;2(5):00068. doi:10.15406/mojor.2015.02.00068
5. Fuentes JP, Armijo Olivo S, Magee DJ, Gross DP. Effectiveness of interferential current therapy, in the management of musculoskeletal pain: a systematic review and meta-analysis. *Phys Ther.* 2010;90(0):1219-1238.-Cloi:10.2522/pt.20090335
6. Ezzati K, Laakso EL, Salari A, Hasannejad A, Fekrazad R, Aris A. The Beneficial Effects of High-Intensity Laser Therapy and Co-Interventions on Musculoskeletal Pain Management: A Systematic Review. *J Lasers Med Sci.* 2020;11(1):81-90. doi:10.15171/jlms.2020.14

Cite this Article: Ekta Kharde, Satyam Bodhaji, Khan Madiha (2023). The Effect of Advanced Laser and Interferential Therapy on the Patient of Pes Anserine Bursitis in Occupational Rehabilitation- A Case Report. International Journal of Current Science Research and Review, 6(6), 3711-3714